

Original article

Brachial plexus endoscopic dissection and correlation with open dissection

Description anatomique de la dissection endoscopique du plexus brachial et corrélations à ciel ouvert

T. Lafosse^{a,*}, E. Masméjean^a, T. Bihel^a, L. Lafosse^b

^a Hand, Upper Limb and Peripheral Nerve Surgery Department, European Georges-Pompidou Hospital, 20, rue Leblanc, 75908 Paris cedex, France

^b Alps Surgery Institute, 74000 Annecy, France

Received 22 June 2015; received in revised form 2 August 2015; accepted 4 August 2015

Available online 12 November 2015

Abstract

Shoulder endoscopy is evolving and becoming extra-articular. More and more procedures are taking place in the area of the brachial plexus (BP). We carried out an anatomical study to describe the endoscopic anatomy of the BP and the technique used to dissect and expose the BP endoscopically. Thirteen fresh cadavers were dissected. We first performed an endoscopic dissection of the BP, using classical extra-articular shoulder arthroscopy portals. Through each portal, we dissected as many structures as possible and identified them. We then did an open dissection to corroborate the endoscopic findings and to look for damage to the neighboring structures. In the supraclavicular area, we were able to expose the C5, C6 and C7 roots, and the superior and middle trunks in 11 of 13 specimens through two transtrapezial portals by following the suprascapular nerve. The entire infraclavicular portion of the BP (except the medial cord and its branches) was exposed in 11 of 13 specimens. The approach to the infraclavicular portion of the BP led directly to the lateral and posterior cords, but the axillary artery hid the medial cord. The musculocutaneous nerve was the first nerve encountered when dissecting medially from the anterior aspect of the coracoid process. The axillary nerve was the first nerve encountered when following the anterior border of the subscapularis medially from the posterior aspect of the coracoid process. Knowledge of the endoscopic anatomy of the BP is mandatory to expose and protect this structure while performing advanced arthroscopic shoulder procedures.

© 2015 SFCM. Published by Elsevier Masson SAS. All rights reserved.

Keywords: Brachial plexus; Anatomical study; Periarticular endoscopy

Résumé

Avec le développement de l'arthroscopie d'épaule au-delà de l'articulation scapulo-humérale, il devient indispensable de maîtriser l'anatomie endoscopique du plexus brachial (PB). Nous avons réalisé une étude cadavérique descriptive de l'anatomie endoscopique du PB et des nerfs autour de l'épaule. Nous avons confronté les constatations endoscopiques avec une dissection à ciel ouvert. Nous avons réalisé la dissection endoscopique du PB de 13 sujets anatomiques par les voies d'abord arthroscopiques de l'épaule. Nous avons disséqué les racines et les troncs, puis les faisceaux et les branches terminales du plexus brachial. Nous avons réalisé une dissection à ciel ouvert pour corroborer les constatations endoscopiques. Dans la région supraclaviculaire, nous avons exposé les racines C5, C6 et C7, les troncs supérieur et moyen, puis avons exposé la partie infraclaviculaire du plexus dans 11 des 13 cas, et le faisceau médial dans 3 cas. Le nerf musculocutané a été vu dans tous les cas, c'était le premier nerf repéré lors de la dissection débutée en avant du processus coracoïde en se dirigeant médialement. Le nerf axillaire était le premier nerf visualisé en débutant la dissection en arrière du processus coracoïde, en se dirigeant médialement. Nous décrivons l'anatomie endoscopique du PB, qu'il est désormais indispensable de maîtriser afin de protéger le plexus dans les interventions endoscopiques de l'épaule se déroulant au-delà de l'articulation. Nous détaillons la technique chirurgicale de l'abord du PB basée sur un travail anatomique de dissection endoscopique, avec une corrélation à ciel ouvert.

© 2015 SFCM. Publié par Elsevier Masson SAS. Tous droits réservés.

Mots clés : Plexus brachial ; Étude anatomique ; Endoscopie périarticulaire

* Corresponding author. 14, rue de Thionville, 75019 Paris, France.

E-mail addresses: lafosse.thibault@gmail.com, thiblaff@gmail.com (T. Lafosse).

1. Introduction

Shoulder arthroscopy techniques have been developing rapidly in recent years. The evolution of arthroscopic techniques allows experienced surgeons to switch from open to arthroscopy procedures. The working space needed to perform these new arthroscopic techniques is becoming larger and extra-articular. Shoulder “arthroscopy” has become “periarticular endoscopy” [1,2]. Surgeons are now able to perform complicated procedures with controlled risks. Nevertheless, shoulder arthroscopy remains technically demanding and is not easily reproducible. In less experienced hands, endoscopy of the periarticular area can be hazardous and severe complications have been reported, including neurological ones [3,4]. The anatomy of the shoulder and the brachial plexus (BP) are interrelated. Periarticular endoscopy takes place close to the BP. The nerves around the shoulder must be located in order to be protected. We started performing endoscopic neurolysis of the BP in 2003 while dissecting the subscapularis muscle during the repair of large and retracted tears [5]. As arthroscopic Latarjet procedures were developed [6], we started dissecting the BP in order to protect it.

In order to describe the endoscopic anatomy of the extra-articular space around the shoulder and the relationships between the nerves and the shoulder, we performed an anatomical study of the endoscopic dissection of the brachial plexus. We compared our findings with those of open dissection. We described the anatomy and the technique for endoscopic dissection of the brachial plexus. The primary aim of the study was to determine if each part of the BP could be identified and dissected by endoscopy. Secondary goals were to precisely describe the endoscopic findings, and to assess which nerves were exposed in each portal.

2. Material and methods

We performed anatomical dissection of fresh cadavers provided by the anatomy laboratory of the surgery school of the Fer à Moulin in Paris. For each cadaver, endoscopic dissection of the supraclavicular part of the brachial plexus (SCBP) and the infraclavicular part of the brachial plexus (ICBP) was performed through pre-defined portals. When the endoscopic dissection was complete, open dissection was performed to verify the endoscopic findings.

The cadavers were placed in a beach chair position, to allow for extended dissection of the BP. The dissections were made using a 5-mm arthroscope, arthroscopy instruments and saline solution. The same surgeon performed all the dissections (T.L.), and one assistant held and manipulated the upper limb of the cadaver in order to facilitate the exposure (T.B.).

Our main outcome criterion was the feasibility of endoscopic nerve exposure. It was considered positive if the nerve could be identified and dissected, and negative if the nerve was not seen, could not be identified precisely, or could not be dissected, even if partially visible.

2.1. Endoscopic portals

Nine portals were used (Fig. 1). There were five supraclavicular portals, and four infraclavicular portals.

2.1.1. Supraclavicular portals

There were two subacromial and two transtrapezial portals. The C portal was a subacromial portal. It was located at the middle of the acromion, 2 cm distal to its lateral border. Through this portal, the target nerves were the suprascapular nerve and the superior trunk. The D portal was a subacromial portal. D was anterolateral, 2 cm distal to the anterior angle of the acromion. Through this portal, the target nerves were the suprascapular nerve and the superior trunk.

The lateral transtrapezial (LT) (TT1 on Fig. 1) and the medial transtrapezial (MT) (TT2 on Fig. 1) portals were both located 2.5 centimeters distal to the upper border of the trapezius. The LT portal was at the level of the suprascapular notch; it was created under endoscopic control from the C and D portals. The target nerves were the suprascapular nerve, the superior, middle and inferior trunks, and the roots of the BP. The MT portal was at the level of the middle of the clavicle. It was created under endoscopic control from the D and LT portals. The target nerves were the trunks and roots of the BP.

The anterior supraclavicular portal was at the level of the middle of the clavicle, immediately posterior to the posterior border of the sternocleidomastoid muscle (arrow on Fig. 1). It was created under endoscopic control from the LT and MT portals. The target nerves through this portal were the trunks and roots of the BP.

2.1.2. Infraclavicular portals

The E portal was anterior, 2 cm distal to the acromioclavicular joint, facing the rotator interval. The target nerves through this portal were the BP cords, the musculocutaneous (MC), axillary and radial nerves from retrocoracoid dissection.

The I portal was in the axis of the coracoid process and across from it, 2 to 3 cm below.

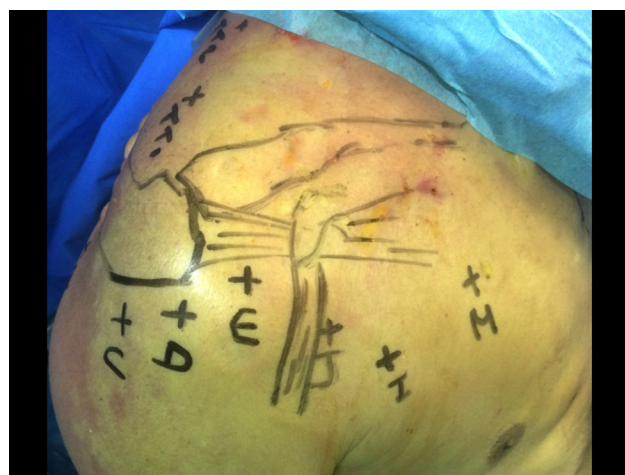


Fig. 1. Supraclavicular and infraclavicular endoscopic portals for the brachial plexus. Arrow: anterior supraclavicular approach; TT1: lateral transtrapezial approach; TT2: medial transtrapezial approach.

The J portal was at the midpoint between the I and D portals.

The M portal was 4 cm distal to the clavicle and 3 cm medial to the coracoid process and the conjoint tendon (CT).

Through the I, J and M portals, the target nerves were the BP cords, the MC, median, axillary, radial and ulnar nerves.

2.2. Dissection stages, surgical technique

2.2.1. Supraclavicular dissection

2.2.1.1. Suprascapular nerve dissection. The first step consisted of releasing the suprascapular nerve (Fig. 2). We used the technique previously described in 2003 by Lafosse et al. [7]. We used the C portal for the scope and the D portal for instrumentation (Fig. 2A) along with the two transtrapezial portals for instrumentation. The LT portal was created under endoscopic control (Fig. 2B), introducing a needle before incising through the trapezius muscle, as previously described. The MT portal was created as previously described, and under endoscopic control, introducing a needle as during the LT portal. The scope was switched to the LT portal and the instrumentation in the MT portal (Fig. 2C). Dissection of the suprascapular nerve was completed.

2.2.1.2. Trunk dissection. The second step was to expose the BP trunks. The scope was placed in the C and LT portals. Instrumentation was placed in the MT portal and the anterior supraclavicular portal (Fig. 2D). After releasing the suprascapular nerve, it was followed proximally until the superior trunk

was reached (ST). The middle trunk was found immediately inferior to it; the inferior trunk (IT) was located immediately below the middle trunk.

2.2.1.3. Root exposure. The scope was placed in the MT portal and the instrumentation was introduced through the anterior supraclavicular portal. They were switched as needed during the dissection (Fig. 2C, D). After the three trunks had been exposed, the dissection was continued proximally into the interscalene triangle. The C5, C6 and C7 roots were found between the posterior border of the anterior scalene muscle and the anterior border of the middle scalene muscle (Fig. 3). The scalene muscle bellies could be followed distally towards their insertion on the first rib, which led to the subclavian artery, the proximal part of the inferior trunk, and the C8 and D1 roots.

2.2.2. Infraclavicular dissection

2.2.2.1. Exposure of the infraclavicular plexus area. The dissection was started from the subacromial area with the scope in the C portal and the instruments in the D portal (Supplementary data, Video S1). The E portal was then created as previously described under endoscopic control using a needle before incising the skin. The CT and coracoid process were dissected, and the retropectoral space was enlarged anteriorly to the coracoid process. The retropectoral space is limited anteriorly by the posterior aspect of the pectoralis major muscle, and posteriorly by the coracoid process and the anterior aspect of the pectoralis minor muscle. This space is an anatomical layer that is found during dissection and enlarged

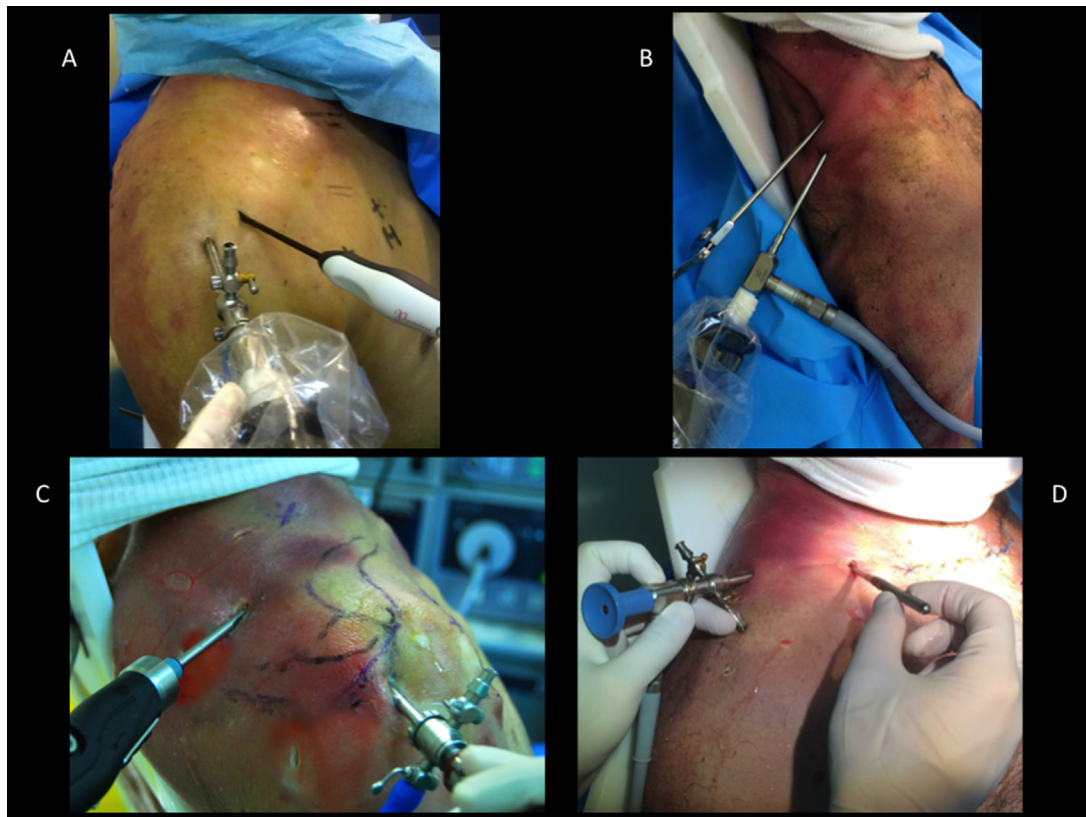


Fig. 2. Supraclavicular plexus dissection, instruments and scope configuration.

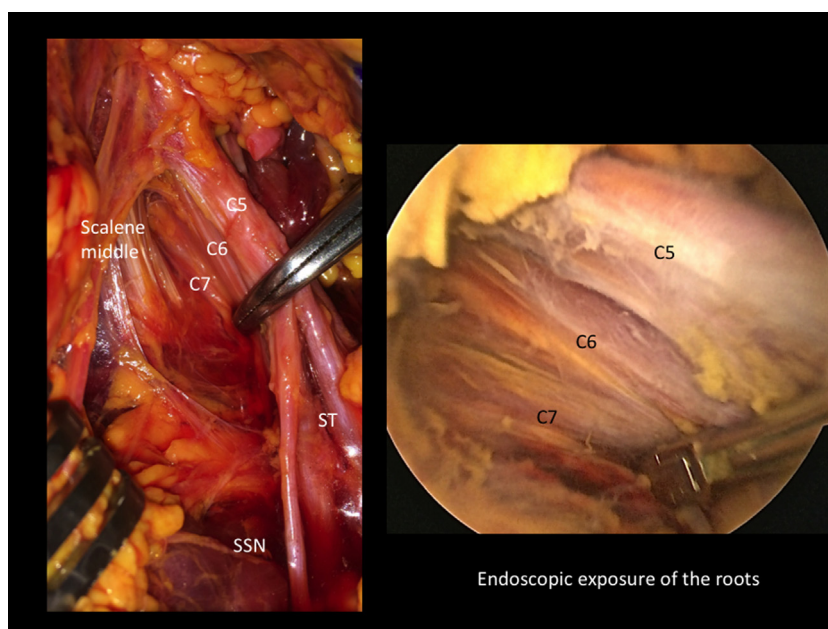


Fig. 3. Endoscopic and open correlation for roots dissection. ST: superior trunk; SSN: suprascapular nerve.

with a smooth trocar, with the water flow helping to expand the space. Any hemostasis required can be performed with a radiofrequency device. The I portal was created under endoscopic control by introducing a needle. The J portal was created at the midpoint between the D and I portals, and the scope was introduced in it. The scope was directly across the coracoid process, and the surgeon could see the pectoralis minor muscle and the CT very clearly. The boundary between the CT and the pectoralis minor muscle bellies was sometimes difficult to see. This was an important area to identify and dissect because it was the only way to safely expose the musculocutaneous nerve, which lies just below.

2.2.2.2. Exposure of the cords. The M portal was created as previously described. It was used to dissect the retropectoral space, the CT, pectoralis minor, and the medial border of the

coracoid process. The axillary artery reaches the brachial plexus from the medial aspect at the level of the cords, which are viewed at the upper border of the pectoralis minor tendon, in the space under the clavicle (Fig. 4). To increase the space under the clavicle, the subclavian muscle can be detached from under the clavicle bone over a distance as large as the width of the three cords. The three cords can thus be followed toward the supraclavicular space. It is possible to reach to the trunks, and clearly view the division of the suprascapular nerve from these scope and instrument positions. Their directions are tangential to the brachial plexus, which can be followed to the interscalene area. This is facilitated by the previous supraclavicular dissection. The space between the CT and the pectoralis minor was then opened and dissected in order to show the musculocutaneous nerve and the terminal branches, with the musculocutaneous nerve being the first to be viewed (Fig. 5).

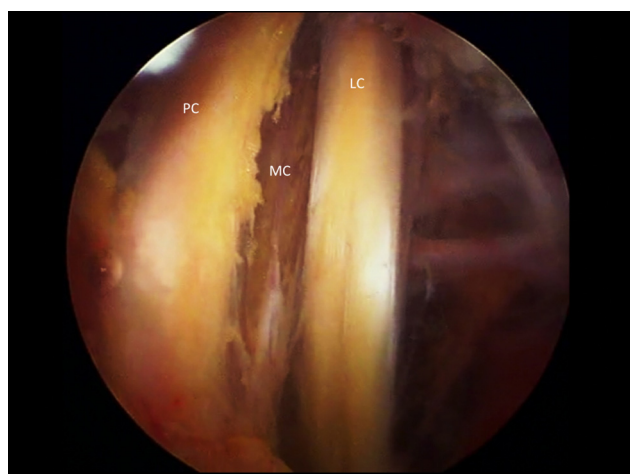


Fig. 4. Endoscopic view of the cords above the upper border of pectoralis minor. PC: posterior cord; MC: medial cord; LC: lateral cord.

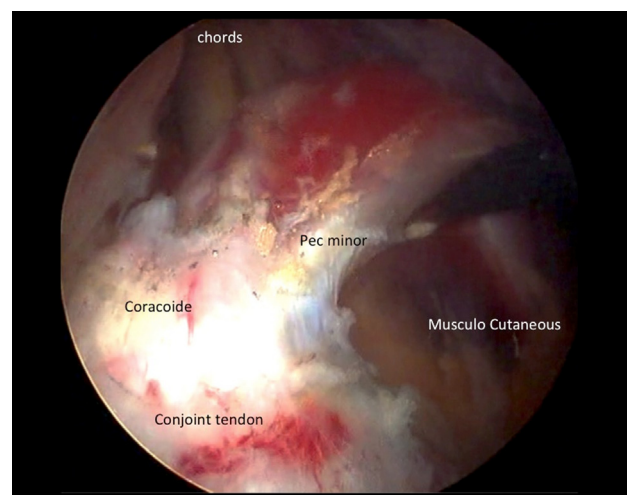


Fig. 5. Infraclavicular plexus endoscopic exposure, before section of the pectoralis minor.

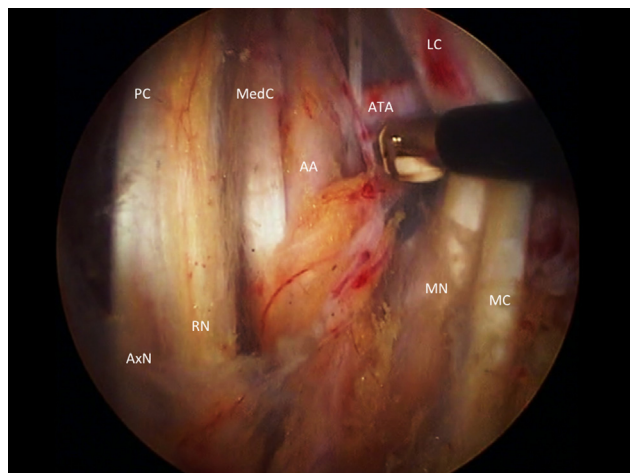


Fig. 6. Endoscopic dissection of terminal branches. PC: posterior cord; Med C: medial cord; LC: lateral cord; Ax N: axillary nerve; RN: radial nerve; MN: median nerve; MC: musculocutaneous nerve; AA: axillary artery; ATA: thoracoacromial artery.

2.2.2.3. Exposure of the terminal branches. To expose the terminal branches, the pectoralis minor was detached from the medial side of the coracoid process. The three cords were followed proximal to distal; the axillary artery reached them at the level of the coracoid process. The ulnar nerve arose from the medial cord. It was seen behind the artery, more medial from the rest of the plexus. It could be found either by following the medial branch on the median nerve proximally, or by reflecting the axillary artery laterally, which made it appear immediately behind (Fig. 6).

2.2.2.4. Retrocoracoid dissection. The retrocoracoid space is limited posteriorly by the anterior aspect of the subscapularis muscle, and anteriorly by the posterior aspect of the coracoid process and the CT (Supplementary data, Video S2). This space

is an anatomical plane; it was dissected with the scope in the D portal and instruments in the E portal. The dissection followed the anterior border of the subscapularis muscle (SSc) posteriorly to the coracoid process and the conjoint tendon. The axillary nerve was the first nerve to be seen through this approach. The radial nerve was found immediately anterior to the axillary nerve when advancing the dissection anteriorly.

Markers were placed at the different levels on the nerve structures in order to correlate the endoscopic and open findings.

2.2.3. Open dissection

The skin was removed and the deltoid, pectoralis major and trapezius muscles were removed to expose the whole BP and the vascular structures. We then verified that our endoscopic findings were correct, completing the dissection when it could not have been done endoscopically. We also verified whether any damage was done to the main neurovascular structures.

3. Results

We dissected 15 brachial plexus complexes on 15 fresh cadavers. The first two dissections were excluded from our analysis since we used them to verify the protocol, to determine whether measurements could be performed or not, and to determine how our endoscopic findings would be analyzed. As a result, the findings from 13 dissected cadavers will be summarized here.

3.1. Supraclavicular dissection

We could see, identify, and dissect the suprascapular nerve in all 13 cadavers (Table 1). The superior and middle trunks, and the C5, C6, and C7 roots could be seen, identified, and dissected in 11 cadavers. In the other 2 cadavers, the fatty tissue made it very difficult to dissect and identify them properly. The exposure of

Table 1
Results of the supraclavicular dissection.

Structure	Endoscopic visualisation	Portal	Open dissection correlation	Iatrogenic lesions
Suprascapular nerve	<i>n</i> = 13	C, D, lateral transtrapezial	Yes	Coracoclavicular ligaments in 2 cases
Superior trunk	<i>n</i> = 11	C, D, lateral and medial transtrapezial	Yes	Transverse cervical artery in 3 cases
Middle trunk	<i>n</i> = 11	C, D, lateral and medial transtrapezial, anterior supraclavicular	Yes	Transverse cervical artery in 3 cases
Inferior trunk	Never			
C5 root	<i>n</i> = 11	C, D, lateral and medial transtrapezial, anterior supraclavicular	Yes	Jugular vein in 1 case
C6 root	<i>n</i> = 11	C, D, lateral and medial transtrapezial, anterior supraclavicular	Yes	Jugular vein in 1 case
C7 root	<i>n</i> = 11	C, D, lateral and medial transtrapezial, anterior supraclavicular	Yes	Jugular vein in 1 case
C8 root	Never			
D1 root	Never			

this part of the plexus was considered negative in those cases. We could never see the inferior trunk and the C8 and D1 roots from the supraclavicular portals described here. The endoscopic findings were consistent with the open dissection findings.

A 2-mm wound was found in the wall of the internal jugular vein in one case, less than one half of the coracoclavicular ligament was cut with the shaver in two cases, and the transverse cervical artery was completely cut in three cases. Through the C, D and LT portals, we could see and expose the suprascapular nerve, the superior and middle trunks, and the C5, C6, C7 roots. Through the MT portal, we could see the superior and middle trunks, and the C5, C6 and C7 roots. Through the anterior supraclavicular portal, we could see the middle trunk and the C5, C6 and C7 roots.

3.2. Infraclavicular dissection

We saw, identified, and dissected the musculocutaneous nerve, the median nerve and the axillary artery in all 13 cadavers (Table 2). The lateral and posterior cords, the radial and axillary nerves, and the lateral thoracic and thoracoacromial arteries could be seen, identified and dissected in 11 cadavers. The medial cord and the ulnar nerve were seen and identified in 11 cadavers but could only be dissected in 3 cadavers. Through the D, E, I, J and M portals, we could see the lateral and posterior cords, along with the musculocutaneous, median, axillary and radial nerves. Through the E, I, J and M portals we could see the medial cord and the ulnar nerve. These structures could not be seen from the D portal. All our endoscopic findings were confirmed by the open dissection.

None of the neurovascular structures were damaged. The musculocutaneous nerve was the first nerve seen when approaching the plexus anteriorly to the coracoid process. The axillary nerve was the first nerve to be seen while approaching the plexus posteriorly to the coracoid process. With this approach, the upper and lower subscapular nerves, which arise directly from the posterior trunk, could be seen in half the cadavers. Their level of emergence was variable. These

are small nerves running directly to the middle of the SSc at the junction between tendon and muscle belly.

4. Discussion

4.1. Anatomical study

We wanted to perform an anatomical dissection focusing on the ease of access of the brachial plexus through portals used in clinical practice. This makes our study unique and different from others such as the one by Garcia et al., as it describes the feasibility of endoscopic dissection of the BP, independent from any shoulder surgery or other everyday practice [8].

Garcia et al.'s portals and dissection technique were different from ours. They used two supraclavicular portals: the first one at the lateral border of the sternocleidomastoid muscle, approximately 5 cm above its attachment on the clavicle, and the second one just above the middle of the clavicle. We used two transtrapezial portals and one anterior supraclavicular portal, but we also used the C and D portals to start the dissection from the subacromial space. We started our dissection from the shoulder and identified the suprascapular nerve first. We then follow it until we found the trunks and roots of the BP, creating the portals under endoscopic control. We perform our dissection distal to proximal. The last portal created was the anterior supraclavicular portal, whereas Garcia et al. started with the supraclavicular portal. They then identified the C5 and C6 roots, and continued the dissection from proximal to distal.

Garcia et al. went further in their dissection of the supraclavicular plexus, since they also exposed the phrenic nerve, long thoracic nerve and dorsal scapular nerve, which we did not. Nevertheless, we believe our technique is safer, since the supraclavicular portals are made under endoscopic control.

Garcia et al. were able to perform infraclavicular dissection with only three portals, the posterior lateral portal (PLP), the lateral portal (LP) and the anterior portal (AP). Our portals were similar to their portals. Our C portal was Garcia et al.'s PLP, our D portal was Garcia et al.'s LP, and our E portal and Garcia et al.'s

Table 2
Results of the infraclavicular dissection.

Structure	Endoscopic visualisation	Portal	Open dissection correlation	Iatrogenic lesions
Musculocutaneous nerve	13 cases	D, E, I, J, M	Yes	Deltoid and pectoral arterial branches
Median nerve lateral root	<i>n</i> = 13	D, E, I, J, M	Yes	Lateral thoracic artery branches
Median nerve medial root	<i>n</i> = 13	D, E, I, J, M	Yes	Id
Median nerve	<i>n</i> = 13	D, E, I, J, M	Yes	Id
Axillary nerve	<i>n</i> = 11	D, E, I, J, M	Yes	None
Radial nerve	<i>n</i> = 11	D, E, I, J, M	Yes	None
Ulnar nerve	<i>n</i> = 3	E, I, J, M	Yes	Lateral thoracic artery branches
Medial brachial cutaneous nerve	<i>n</i> = 1	E, I, J, M	Yes	Id
Lateral cord	<i>n</i> = 11	D, E, I, J, M	Yes	Id
Posterior cord	<i>n</i> = 11	D, E, I, J, M	Yes	Id
Medial cord	<i>n</i> = 3	E, I, J, M	Yes	Id
Subscapularis nerves	Half of cases	D, E, I, J	Yes	None
Axillary artery	<i>n</i> = 13	D, E, I, J, M	Yes	Deltoid and pectoral arterial branches, lateral thoracic artery branches

Id: idem.

AP appear similar. Nevertheless, we also had an I portal facing the coracoid process, 3 cm below it, and a J portal, located at the midpoint between I and D portals. We also describe a very medial portal, the M portal that was not used by Garcia et al.

Finally, one of the biggest differences is that our portals are existing portals, previously used in arthroscopic shoulder procedures, typically the arthroscopic Latarjet procedure [9].

4.2. Clinical experience

In our clinic, more than 60 patients have undergone endoscopic infraclavicular plexus release with pectoralis minor transection. More than 150 patients have undergone suprascapular nerve release, many of which were released very proximally close to the superior trunk [5]. Two-thirds of them underwent endoscopic plexus release for an infraclavicular thoracic outlet syndrome [10], and one-third had it performed along with an extra-articular endoscopic procedure such as arthroscopic Latarjet, repair of large subscapularis tears, arthrolysis, or Latarjet revision with bone block procedure [3]. All these surgeries took place in an area of the shoulder far away from the glenohumeral joint and close to the brachial plexus.

We defined three areas around the shoulder according to the location of neurovascular structures: “anterior shoulder”, “posterior superior shoulder” and “inferior shoulder” (Fig. 7). Three lines starting from the center of the glenoid cavity delimit these three areas. The “anterior shoulder” is defined by the lines going to the base of the coracoid process and the inferior border of the subscapularis muscle. The “posterior superior shoulder” is defined by the lines going to the base of the coracoid process and to the teres minor muscle. The lines going to the teres minor muscle and the inferior border of the subscapularis muscle define the “inferior shoulder”.

The “anterior shoulder” contains the brachial plexus, the axillary artery and its branches. The “posterior superior shoulder” contains the suprascapular nerve, and the SCBP. The “inferior shoulder” contains the axillary nerve.

The “anterior shoulder” is where most of the extra-articular endoscopic surgeries take place [1,2]: large subscapularis tears, arthroscopic Latarjet, revisions of Latarjet with bone blocks, arthrolysis. We started to dissect the brachial plexus and its branches while performing these types of surgical procedures,

on one hand because it became necessary to identify the nerves to locate them in order to protect them and on the other because during revision procedures, the nerves have significant adhesions, and it is mandatory to dissect the BP in order to protect it. We have now performed more than 60 clinical cases of infraclavicular brachial plexus endoscopic release in thoracic outlet syndrome (TOS), and during revisions or complex endoscopic shoulder procedures. These patients are currently being reviewed, and we are using the DASH score to evaluate the results of endoscopic TOS release.

During our clinical experience with endoscopic surgery in the “anterior shoulder”, we noticed that the first nerve to be seen from an anterior approach of the coracoid was the musculocutaneous nerve, and the first one identified posteriorly to the coracoid process and from the anterior aspect of the SSc was the axillary nerve [11,12]. We were able to confirm this in our anatomical study. We also found that aside from the C8 and D1 roots and the inferior trunk, the brachial plexus is almost completely accessible through the usual arthroscopic portals. This confirms our hypothesis that the nerves could easily be damaged during current shoulder arthroscopy procedures [13].

4.3. Technical difficulty

The C8 and D1 roots and the inferior trunk were not accessible to dissection in our study. This can be explained by the fact that they are very distal and inferior to the portals we used. The inferior limit of our dissection was the middle trunk and the C7 root. In order to correctly see the inferior trunk and the C8 and D1 roots, the subclavian artery would have to be dissected, but it was always too far from our portals, and difficult to perform without damaging the artery. Garcia et al. were not able to approach the C8 and D1 roots and the inferior trunk either [8]. Nevertheless, the inferior trunk and roots could be accessed by following the edges of the scalene muscles, which lead to the first rib. We think that the only solution to approaching this area safely by endoscopy is to use the axillary portal for the Da Vinci robot described by Tetik and Uzun [14].

During the infraclavicular dissection, the medial trunk and ulnar nerve could only be exposed and dissected in 3 cases out of 13. In other eight cases, we could see where these structures were located, but they were not accessible through an efficient and safe dissection from the portals we were using. The difficulty of accessing these structures can be explained by the fact that our anterior portals are still somewhat lateral. The first structures seen are the lateral cord and the musculocutaneous nerve, which are relatively anterior from the scope’s point of view. From an anatomical point of view the posterior cord, axillary and radial nerves are immediately posterior to this. Nonetheless from the scope’s point of view, they are lateral to the lateral cord and the musculocutaneous or median nerve. Still from the scope’s point of view, the axillary artery is posterior to this previously described structure; therefore, the medial trunk and the ulnar nerve were always behind the axillary artery, and even though they are a medial structure from an anatomical point of view, they were always posterior, and behind our scope’s point of view from the portals we used. This

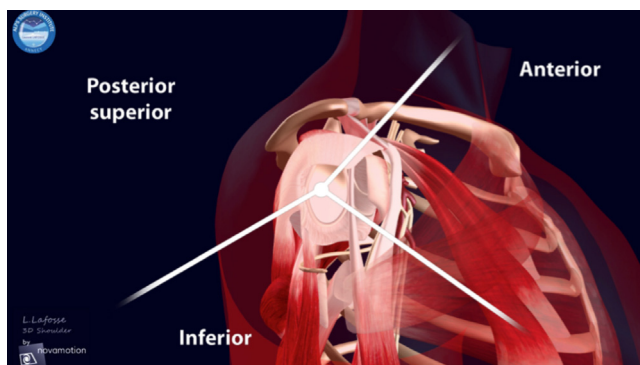


Fig. 7. Compartments of the shoulder.

make them the furthest structures from our working space in the “anterior shoulder”, thus the most difficult to dissect.

4.4. Limits of the study

We performed our study with saline inside the joint. Other endoscopic studies have been done using air [15,16]. It is undeniable it is much easier to see anatomical structures in air than the fluid. The dissection products will not float around in the middle of the field of vision when using air. Nevertheless, our study focused on exploring the brachial plexus from an arthroscopic point of view and around the shoulder. We felt it was important to reproduce the arthroscopic situation, show how a shoulder surgeon should manage the proximity of the nerves, and show how they should be dissected.

We decided to present our results without measurements. This can be criticized for an anatomical study. Indeed one would want to have quantitative data in order to have landmarks and reproduce the technique. Nevertheless, we felt it was impossible to give quantitative data to mark the different structures at a certain distance of the skin, for several reasons:

- first, swelling: the distance between the skin and neurovascular structures increases as the shoulder and the body swell up with arthroscopy fluid;
- second, this distance varies with the position of the shoulder and the body, since all the neurovascular structures are free to move relative to one another [17]. We tried to take measurements during our first two dissections, but realized they were not going to be relevant, that a very large number of cadavers would be needed to draw conclusions, and that it was not the aim of our study.

Our main goal was to describe a technique, in which we use body landmarks instead of measurements, and to describe a specific method of creating new portals under endoscopic control. And using this method, we wanted to dissect the BP.

5. Conclusion

We were able to dissect and expose the brachial plexus endoscopically. Except for the C8 and D1 roots and lower trunk of BP, we were able to describe precisely the endoscopic anatomy of the BP. The supraclavicular portion of the plexus is technically difficult and hazardous to dissect. The infraclavicular plexus dissection is feasible and reproducible, but the lower trunk and ulnar nerve are difficult to dissect.

This dissection is required during many shoulder arthroscopic procedures taking place outside of the glenohumeral joint. We have described an endoscopic technique for dissecting the brachial plexus that can be applied to nerve exploration and protection while performing shoulder arthroscopy, or in order to approach the nerves endoscopically during robotic surgery [16,18].

Disclosure of interest

The authors declare that they have no competing interest.

Acknowledgement

Dr Benoît Villain for his great help.

Appendix A. Supplementary data

Supplementary data associated with this article can be found, in the online version, at <http://dx.doi.org/10.1016/j.main.2015.08.007>.

References

- [1] Boyle S, Haag M, Limb D, Lafosse L. Shoulder arthroscopy, anatomy and variants – part 1. *Orthop Trauma* 2009;23:291–6.
- [2] Boyle S, Haag M, Limb D, Lafosse L. Shoulder arthroscopy, anatomy and variants – part 2. *Orthop Trauma* 2009;23:365–76.
- [3] Ho E, Cofield RH, Balm MR, Hattrup SJ, Rowland CM. Neurologic complications of surgery for anterior shoulder instability. *J Shoulder Elbow Surg* 1999;8:266–70.
- [4] Griesser MJ, Harris JD, McCoy BW, Hussain WM, Jones MH, Bishop JY, et al. Complications and re-operations after Bristow-Latarjet shoulder stabilization: a systematic review. *J Shoulder Elbow Surg* 2013;22:286–92.
- [5] Lafosse L, Piper K, Lanz U. Arthroscopic suprascapular nerve release: indications and technique. *J Shoulder Elbow Surg* 2011;20(2 Suppl.) S9–13.
- [6] Lafosse L, Lejeune E, Bouchard A, Kakuda C, Gobezie R, Kochhar T. The arthroscopic Latarjet procedure for the treatment of anterior shoulder instability. *Arthrosc J Arthrosc Relat Surg* 2007;23:1242.e1–e.
- [7] Lafosse L, Tomasi A, Corbett S, Baier G, Willems K, Gobezie R. Arthroscopic release of suprascapular nerve entrapment at the suprascapular notch: technique and preliminary results. *Arthrosc J Arthrosc Relat Surg* 2007;23:34–42.
- [8] Garcia Jr JC, Mantovani G, Liverneaux P-A. Brachial plexus endoscopy: feasibility study on cadavers. *Chir Main* 2012;31:7–12.
- [9] Lafosse L, Boyle S. Arthroscopic Latarjet procedure. *J Shoulder Elbow Surg* 2010;19:2–12.
- [10] Vemuri C, Wittenberg AM, Caputo FJ, Earley JA, Driskill MR, Rastogi R, et al. Early effectiveness of isolated pectoralis minor tenotomy in selected patients with neurogenic thoracic outlet syndrome. *J Vasc Surg* 2013;57:1345–52.
- [11] Fogerty S, Dumont GD, Lafosse L. Shoulder arthroscopy: the past, present and future directions. *Orthop Trauma* 2014;28:378–87.
- [12] Lafosse L, Lanz U, Saintmard B, Campens C. Arthroscopic repair of subscapularis tear: surgical technique and results. *Orthop Traumatol Surg Res* 2010;96(8 Suppl.)S99–108.
- [13] Delaney RA, Freehill MT, Janfaza DR, Vlassakov KV, Higgins LD, Warner JJ. Neuromonitoring the Latarjet procedure. *J Shoulder Elbow Surg* 2014;23:1473–80.
- [14] Tetik C, Uzun M. Novel axillary approach for brachial plexus in robotic surgery: a cadaveric experiment. *Minim Invasive Surg* 2014;927456.
- [15] Porto de Melo PM, Garcia JC, Montero EF, de S, Atik T, Robert E-G, et al. Feasibility of an endoscopic approach to the axillary nerve and the nerve to the long head of the triceps brachii with the help of the Da Vinci robot. *Chir Main* 2013;32:206–9.
- [16] Miyamoto H, Leechavengvongs S, Atik T, Facca S, Liverneaux P. Nerve transfer to the deltoid muscle using the nerve to the long head of the triceps with the da Vinci robot: six cases. *J Reconstr Microsurg* 2014;30:375–80.
- [17] Massimini DF, Singh A, Wells JH, Li G, Warner JJ. Suprascapular nerve anatomy during shoulder motion: a cadaveric proof of concept study with implications for neurogenic shoulder pain. *J Shoulder Elbow Surg* 2013;22:463–70.
- [18] Facca S, Hendriks S, Mantovani G, Selber JC, Liverneaux P. Robot-assisted surgery of the shoulder girdle and brachial plexus. *Semin Plast Surg* 2014;28:39–44.